

**TECHNICAL NOTE**

Guy N. Ruty,<sup>1</sup> M.D., M.B.B.S., F.R.C.Path., Dip.R.C.Path.(Forensic), F.F.S.Soc., F.F.F.L.M.;  
Claire Robinson,<sup>2</sup> B.Sc., M.Sc.; Bruno Morgan,<sup>2</sup> Ph.D., B.M.B.Ch., M.R.C.P., F.R.C.R.; Sue Black,<sup>3</sup>  
O.B.E., B.Sc., Ph.D., D.Sc., F.R.S.E.; Catherine Adams,<sup>4</sup> D.C.R.R., B.D.S. (Wales), M.S.C., R.F.P.;  
and Philip Webster,<sup>5</sup> H.D.C.R., D.M.S., M.B.A.

## Fimag: The United Kingdom Disaster Victim/Forensic Identification Imaging System

**ABSTRACT:** Imaging is an integral diagnostic tool in mass fatality investigations undertaken traditionally by plain X-rays, fluoroscopy, and dental radiography. However, little attention has been given to appropriate image reporting, secure data transfer and storage particularly in relation to the need to meet stringent judicial requirements. Notwithstanding these limitations, it is the risk associated with the safe handling and investigation of contaminated fatalities which is providing new challenges for mass fatality radiological imaging. Mobile multi-slice computed tomography is an alternative to these traditional modalities as it provides a greater diagnostic yield and an opportunity to address the requirements of the criminal justice system. We present a new national disaster victim/forensic identification imaging system—Fimag—which is applicable for both contaminated and non-contaminated mass fatality imaging and addresses the issues of judicial reporting. We suggest this system opens a new era in radiological diagnostics for mass fatalities.

**KEYWORDS:** forensic science, Fimag, computed tomography, MSCT, odontology, anthropology, mass fatality

Radiological imaging has become an integral diagnostic tool in mass fatality investigations. At present up to three different radiological techniques may be used in the investigative process: fluoroscopy, principally as a metallic foreign body screening tool, plain X-ray for bone examination, and dental X-ray (1). This approach raises issues concerning equipment sourcing and availability, numbers of trained and accredited operational personnel, and radiation exposure risks to those operating and working near the equipment within a temporary facility. To date there are no formal protocols or means to secure raw data storage, and images are frequently viewed by personnel without formal training or accreditation. Formal image reports are not generated and the option of scene-based radiology, for example in the investigation of contaminated fatalities is not available. Finally invasive autopsy procedures including soft tissue resection, periosteal stripping, and bone cleaning remain a requirement for pathological, odontological, and anthropological examinations. These procedures are both time consuming and raise significant issues pertaining to health and safety concerns.

Here we present a new national integrated disaster victim/forensic identification imaging system, *Fimag* which we believe addresses all of these issues. The evidence base, operational infrastructure, and key personnel for this system are in place but matters

regarding operational protocols, workstation placement, training, and research are under active development and review.

We have previously reported the concept and first use of multi-slice computed tomography (MSCT) for mass fatality investigations (2,3). Drawing upon this experience and through further research and exercises we have considered the needs of the professional bodies involved in the investigation, the requirements of the criminal justice system, and the daily work of clinical diagnostic radiological networks. By uniting these bodies for the first time, we present a new radiological diagnostic framework for mass fatality investigations that is robust, cohesive, judicially sound and can operate at both a national and an international level in both contaminated and non-contaminated events (Fig. 1).

The realization of the potential diagnostic role of MSCT in forensic investigations, the increased availability of static hospital or mortuary located scanners, and the pursuit of the so-called “non-invasive” radiological autopsy has resulted in MSCT becoming the principal choice for radiological imaging where available (4–6). However the forensic diagnostic use of mobile MSCT has been limited to date (7). MSCT can be used to image whole and disrupted cadavers within sealed normal or specially designed chemical, biological, and radiological (CBR) body bags without the necessity for direct cadaver operator handling. We have identified that they are ideally suited to scene, indoor, or outdoor temporary mortuary located imaging (Fig. 2). We have previously reported that 2D localizer images and a volumetric data set, allowing 2D and 3D reconstructions in any plane can all be acquired in approximately 15 min within a self-contained, purpose-built unit (2). This can be run to standardized forensic operating procedures for imaging and cadaver movement on and off the vehicle.

In anticipation of potentially multiple concurrent incidents occurring at different locations we have adopted the use of three

<sup>1</sup>East Midlands Forensic Pathology Unit, University of Leicester, Robert Kilpatrick Building, Leicester Royal Infirmary, Leicester LE2 7LX, UK.

<sup>2</sup>Imaging Department, Leicester Royal Infirmary, Leicester LE2 7LX, UK.

<sup>3</sup>Centre for Anatomy and Human Identification, University of Dundee, Dundee DD1 5EH, UK.

<sup>4</sup>Expert Forensics, Cardiff Medicentre, Heath Park, Cardiff CF14 4UJ, UK.

<sup>5</sup>Department of Health, New Kings Beam House, 22 Upper Ground, London SE1 9BW, UK.

Received 29 Aug. 2008; and in revised form 11 Nov. 2008; accepted 26 Nov. 2008.

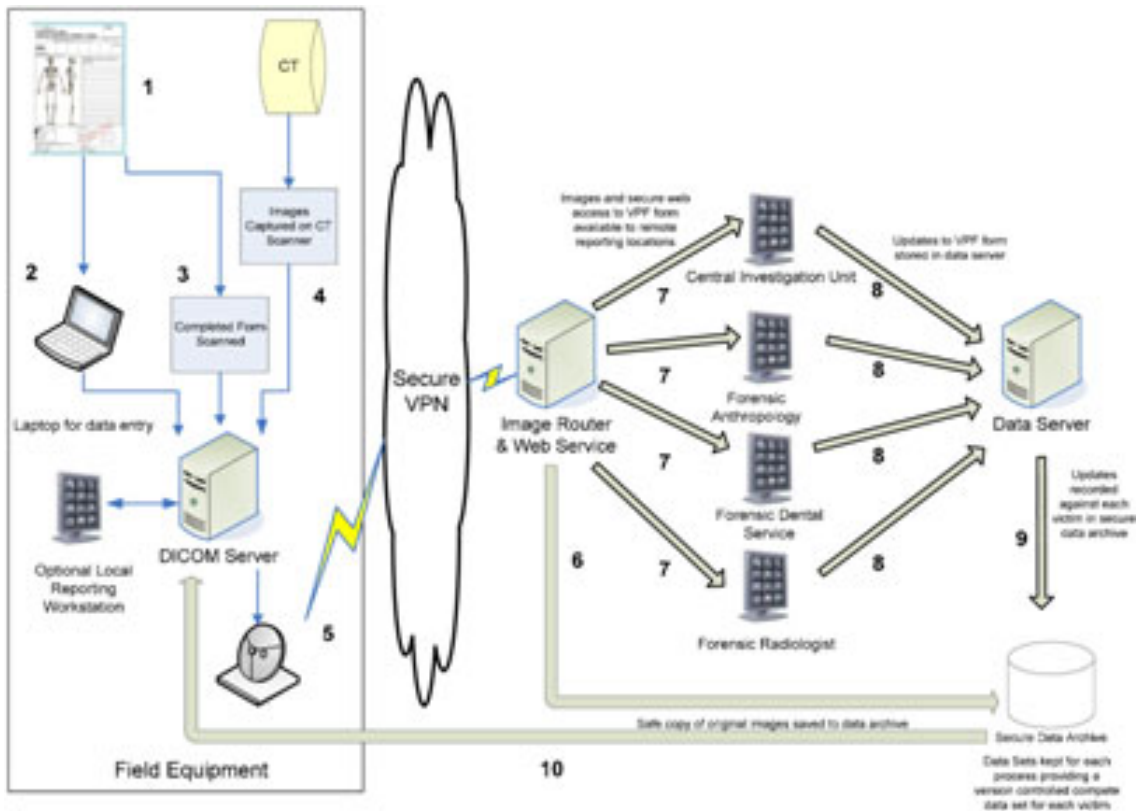


FIG. 1—The UK disaster victim/forensic identification imaging service (Fimag). 1. ACPO victim identification form and or Interpol F1 and F2 forms (VPF) completed. 2. VPF record created on on-line database. 3. VPF form scanned into system to capture data. 4. Images captured on MSCT and forwarded to field DICOM server. 5. Data and images transferred to FPacs image router and web server. 6. Secure source data stored on FPacs data archive. 7. Images forwarded to remote reporting workstations. 8. Remote reporting use the FRIs to update the VPF using secure online web server. 9. Updates stored on FPacs data archive. 10. The field team access victim reports and images from the data archive.

(expanding to eight in 2009) modified mobile 16 detector MSCT for this system. The modifications required pertain to the use for contaminated bodies where the safe working environment for personnel is paramount and, for example, continuous CCTV monitoring of the internal cabin is required. Once operational a unique data entry is initiated by the radiographers using a secure online database for each body or body part (referred to as “body” from this point onwards). Data entry is based on the national victim identification number system presented with the body on the Association of Chief Police Officers (ACPO) body recovery form and/or the Interpol forms (Victim Profile Form [VPF]) (Fig. 1, parts 1–3.). Scanning is then undertaken using set forensic protocols based on the need to capture pathology, identification information, and investigative images (Fig. 1, part 4). The principal limitation to the system is the volume of images generated, total file size and issues related to X-ray tube overheating that can slow the scanning process, all of which are taken into account within the operating protocols. The data is transferred to the field-based support DICOM server which is located within a converted mobile MSCT vehicle stripped of the operational scanner equipment. This vehicle acts as a data hub and field-reporting vehicle as images can be viewed and reported if required on a field-reporting workstation. As it maintains its expandable lead-lined room this can be fitted and used with portable plain X-ray and fluoroscopy equipment as a backup to the principal MSCT imaging should these modalities be considered to be required in any given incident.

Encrypted raw DICOM data is sent from the support server via telephone line, 3G or satellite networks using secure Virtual Private

Network (VPN) to the Forensic Picture Archiving System (FPacs) Image Router and Web server (Fig. 1, part 5). Here it is split such that an original set of raw data is forwarded to a national secure FPacs Data Archive for permanent storage (Fig. 1, part 6). Images and access to the VPF are then made available at remote reporting locations (Fig. 1, part 7). This can be within clinical imaging departments, specialist forensic investigative units, or dedicated victim identification matching centers anywhere in the world. Due to the cost associated with setting up this network and the variety of DICOM workstations and viewers used in clinical practice we have adopted a single DICOM viewer.

Reporting teams are established for each principal profession that utilizes radiological imaging during mass fatality investigations with an overall central investigation unit overseeing the process. The forensic radiology team comprises consultant radiologists from a background of adult and child forensic, trauma, and general CT reporting. This group works in real time as the reports generated by them have a direct bearing on the subsequent field examinations. MSCT allows visualization of soft tissues, bones, and inanimate objects including metals, woods, and plastics. Each case is assessed for natural and unnatural pathology, foreign objects, and parameters that can be utilized for identification purposes. This can reduce the necessity to undertake invasive autopsies on incidental victims as opposed to subjects of interest, e.g., the train driver, the pilot of the plane, or the suspected terrorist. It can be used to identify risks to the pathologists for example unexploded ordnance, broken bones, or foreign bodies including metal and glass as well as materials of interest for forensic investigators such as

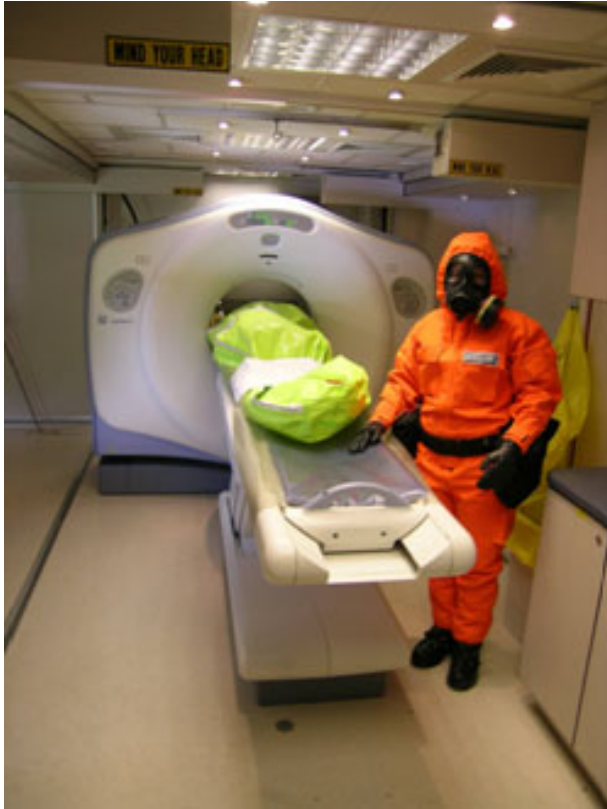

FIG. 2—Mobile MSCT for contaminated mass fatality investigations. A simulated contaminated cadaver is processed by operational staff wearing personal protective equipment.

components from improvised devices. They utilize the Forensic Radiology Information System (FRis) entering reports onto the VPF using a secure online web form. This allows for selected DICOM images to be inserted into the reports, for example to allow those in the field to visualize the pathologies and identifying features such as a prosthesis or location of a foreign body of forensic interest (Fig. 1, part 8). This data updates the FPacs data archive (Fig. 1, part 9) and is forwarded back to the field server so that the pathology team have a formal radiology report to assist the investigative process prior to examination of the body (Fig. 1, part 10). This can be viewed by the pathologists prior to an autopsy examination within the hub vehicle or displayed in front of them on mortuary-located plasma screens. Two- and 3D images (static or movie formats) can also be subsequently prepared from the archive for criminal justice purposes.

Odontologists have a significant role in victim identification and are usually mortuary based. However, again MSCT can replace traditional X-ray dental imaging using standard clinical software such as Dentascan® (GE Healthcare, Chalfont St Giles, UK) (8–11) and compared to antemortem dental X-rays. This is supplemented by field dental photography. For contaminated cases remote dental charting may be achieved using pathology team head-mounted or overhead fixed camera systems. Data is entered into the FRis to assist victim identification. We are not promoting the removal of forensic odontologists from mass fatality investigation but rather, by introducing modern radiological techniques and image capturing systems provide an alternative working scenario which, in the case of contaminated fatalities, ensures their continued role in the investigative process without close exposure to potentially life-threatening agents.

Anthropologists may form part of a mass fatality investigative team depending on the nature of the incident. Although normally located in the mortuary, an expanded role of MSCT is becoming recognized as a tool for anthropology as the skeleton can be visualized in both 2D and 3D without the necessity to deflesh bones, a time-consuming process to be avoided wherever possible when working with contaminated cadavers (12–15). Although re-association of body parts can be achieved using DNA technology, a more immediate identification and matching of body parts can arise through the use of anatomically trained forensic anthropologists and we have recently reported the concept of tele-anthropology for mass fatality investigations utilizing this system (16). The anthropology team access the FRis and undertake bone assessment and measurements, entering the data into anthropology data sets (Fig. 3) for victim identification. Again, we do not propose the loss of the anthropologist from the investigative team but rather an expanded role in incidents where an anthropologist may not have been previously utilized. An anthropology team can now be engaged remotely in all incidents using the Fimag system.

MSCT also allows for other disciplines and systems to be used within the FRis. Facial reconstruction can be applied to MSCT data (17). External soft tissue visualization in 3D can enable parts of the Interpol victim identification forms to be assessed remotely (18) (Fig. 4). All of this can be captured and stored on the FPacs to assist the investigative or criminal justice systems. Facial mapping/superimposition, a system used in both criminal investigation and mass fatality identification, for example the Asian Tsunami 2005, is also possible with 3D reconstructed MSCT images. This could be of particular importance in those cases, both adult and children, where dental records are not available or with contaminated fatalities where opening of the body bag should be avoided.

Finally the use of MSCT deployed with secure image routing and a data transfer system capable of delivering images and reports into any Hospital Radiology Information and Picture Archiving Systems has the possibility to support response to major incidents involving live casualties. This could be used either as on-site trauma assessment or dependent on deployment time—to increase MSCT capacity to units who have admitted large numbers of trauma cases for assessment, poststabilization.

By utilizing the Fimag system we introduce a new era in mass fatality radiology. The number of scene-based personnel, radiological modalities, and invasive autopsy procedures are reduced which is critical for safe working practices particularly when faced with contaminated fatalities. Rapid permanent secure data handling and storage is achievable. Remote image reporting for pathological and identification purposes is performed by appropriate professionals rather than the *ad hoc* system that has existed until now. The U.K. investment in equipment, training, software development and technology infrastructure is considered future proof and will support areas of research and development in the fields of forensic radiography and the non-invasive autopsy for the foreseeable future.

#### Acknowledgments

We wish to thank Alliance Medical (Warwick, UK) and Burnbank, (Ipswich, UK) for their support during the research and exercise phases of the development of this system. Additional research support was provided by the members of the East Midlands Forensic Pathology Unit. We wish also to thank the radiographers of the national CBRN “ology” response team for their assistance in the development of the scene-based system.

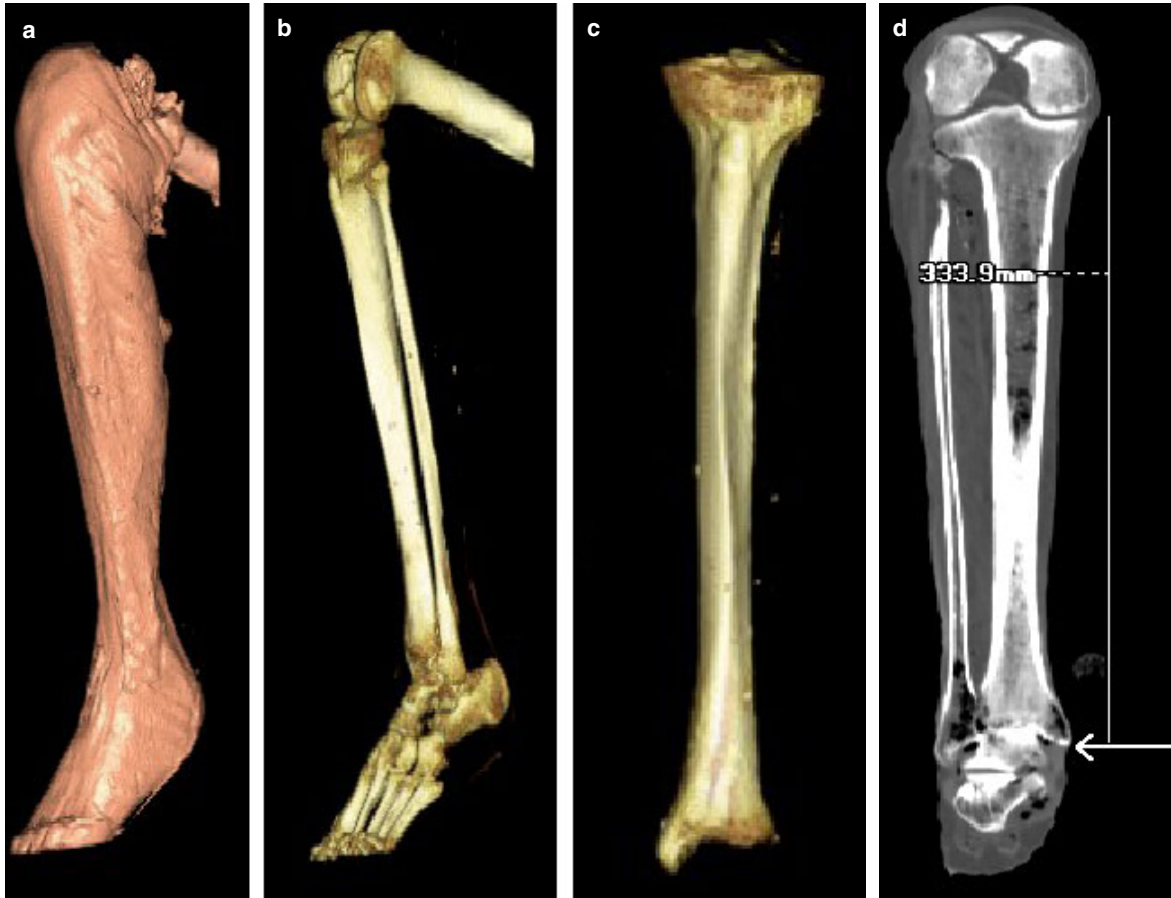


FIG. 3—MSCT tele-anthropology. (a) A fleshed lower limb is scanned, (b) Using the CT software the limb is “virtually” defleshed, (c) Single bones can be isolated and examined in 3D, (d) isolated bones can be aligned and anthropological measurements taken.

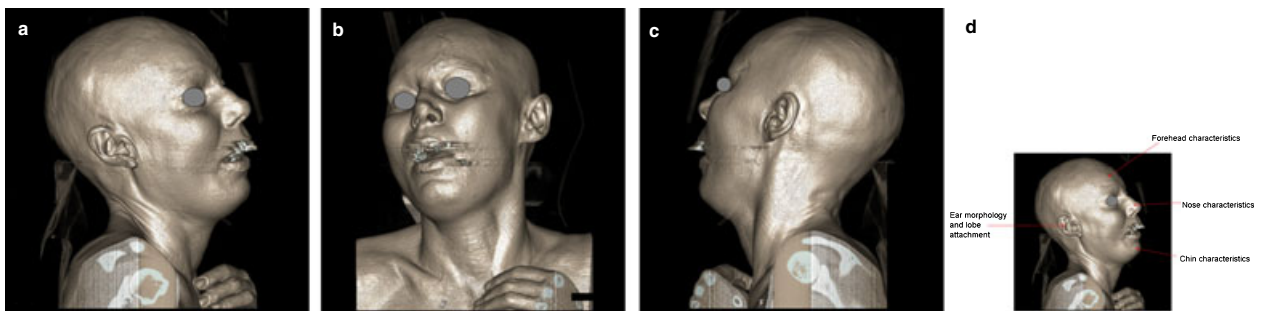


FIG. 4—MSCT for victim identification. (a–c) Using soft tissue window MSCT can provide external soft tissue imaging in 3D, (d) The images can be used to fill out assessment criteria found within standardized systems such as the Interpol victim identification form (Toishiba 64 detector MSCT).

## References

- Guidance for dealing with fatalities in emergencies. Joint Publication: Home Office and Cabinet Office. Home Office Communication Directorate, 2004, <http://www.cabinetoffice.gov.uk/media/132748/fatalities.pdf>.
- Rutty GN, Robinson CE, BouHaidar R, Jeffery AJ, Morgan B. The role of mobile computed tomography in mass fatality incidents. *J Forensic Sci* 2007;52:1343–9.
- Rutty GN, Robinson CE, Jeffery A, Morgan B. Mobile computed tomography for mass fatality investigations. *Forensic Sci Med Pathol* 2007;3:138–45.
- Thali MJ, Yen K, Schweitzer W, Vock P, Boesch C, Ozdoba C, et al. Virtopsy, a new imaging horizon in forensic pathology: virtual autopsy by postmortem multislice computed tomography (MSCT) and magnetic resonance imaging (MRI)—a feasibility study. *J Forensic Sci* 2003;48:386–403.
- Leth PM. The use of CT scanning in forensic autopsy. *Forensic Sci Med Pathol* 2007;3:65–9.
- O'Donnell C, Rotman S, Collett S, Woodford N. Current status of routine post-mortem CT in Melbourne, Australia. *Forensic Sci Med Pathol* 2007;3:226–32.
- Hayakawa M, Yamamoto S, Motani H, Yamima D, Sato Y, Iwasw H. Does imaging technology overcome problems of conventional post-mortem examination? *Int J Legal Med* 2006;120:24–6.
- Jackowski C, Aghayev E, Sonnenschein M, Dirnhofner R, Thali MJ. Maximum intensity projection of cranial computed tomography data for dental identification. *Int J Legal Med* 2006;120:165–7.
- Jackowski C, Wyss M, Persson A, Classens M, Thali MJ, Lussi A. Ultra-high-resolution dual-source CT for forensic dental visualization—discrimination of ceramic and composite fillings. *Int J Legal Med* 2008;122:301–7.

10. Jackowski C, Lussi A, Classens M, Kilchoer T, Bolliger S, Aghayev E, et al. Extended CT scale overcomes restoration caused streak artifacts for dental identification in CT-3D color encoded automatic discrimination of dental restorations. *J Comput Assist Tomogr* 2006;30:510-3.
11. Thali MJ, Markwalder T, Jackowski C, Sonnenschein M, Dirnhofer R. Dental CT imaging as a screening tool for dental profiling: advantages and limitations. *J Forensic Sci* 2006;51:113-9.
12. Weber GW, Recheis W, Scholze T, Seidler H. Virtual anthropology (VA): methodological aspects of linear and volume measurements—first results. *Coll Antropol* 1998;22:575-84.
13. Verhoff MA, Ramsthaler F, Krähhahn J, Deml U, Gille RJ, Grabherr S, et al. Digital forensic osteology—possibilities in cooperation with the Virtopsy project. *Forensic Sci Int* 2007;174:152-6.
14. Reid A, Schneider-Kolsky ME, O'Donnell CJ. Comparison of computed radiography and multi-detector computed tomography in the detection of post mortem metacarpal index. *Forensic Sci Int* 2008;177:192-8.
15. Dedouit F, Telmon N, Costagliola R, Otal P, Florence LL, Joffre F, et al. New identification possibilities with postmortem multislice computed tomography. *Int J Legal Med* 2007;21:507-10.
16. Robinson C, Eisma R, Morgan B, Jeffery A, Graham EAM, Black S, et al. Anthropological measurement of lower limb and foot bones using multi-detector computed tomography. *J Forensic Sci* 2008;53(6):1289-95.
17. Wilkinson C, Rynn C, Peters H, Taister M, Kau CH, Richmond S. A blind accuracy assessment of computer-modeled forensic facial reconstruction using computed tomography data from live subjects. *Forensic Sci Med Pathol* 2006;3:179-88.
18. Sidler S, Jackowski C, Dirnhofer D, Vock P, Thali M. Use of multislice computed tomography in disaster victim identification—advantages and limitations. *Forensic Sci Int* 2006;169:118-28.

Additional information—reprints not available from author:

Guy N. Ritty, M.D., M.B.B.S.  
East Midlands Forensic Pathology Unit  
University of Leicester  
Robert Kilpatrick Building  
Leicester Royal Infirmary  
Leicester LE2 7LX  
UK  
E-mail: gnr3@le.ac.uk